

## DiLumen™ - Assisted Complex Sigmoid Polyp Resection

A Case Report

---

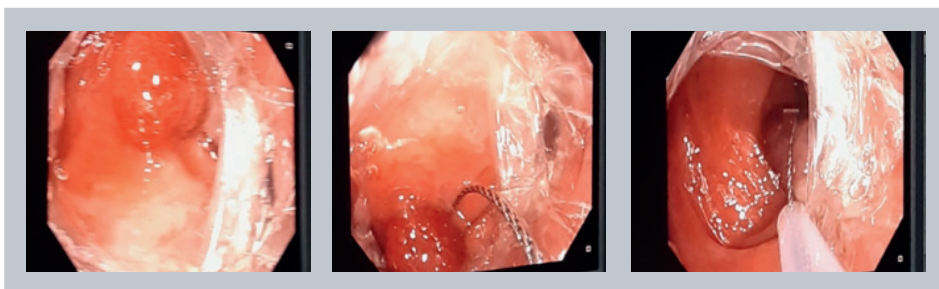
### Patient History:

Following two previous unsuccessful endoscopic attempts to remove a 20mm pedunculated pre-cancerous lesion in the sigmoid colon, this 50-year-old male patient was referred to Hospital General Universitario de Alicante for possible surgical removal of the lesion. The two previous attempts failed due to scope instability and lesion visibility- hidden behind the fold. The polyp was situated at a complex location behind a fold in the sigmoid. The lesion was discovered after the patient reported blood in his stool. The patient had no other relevant medical history. A decision was made to attempt a third endoscopic approach utilizing a double balloon device to aid in visualization and stabilization before surgery.

---

### Procedure:

The DiLumen™ Endoluminal Interventional Platform assisted polypectomy was performed under deep sedation in the Endoscopy Suite at Hospital General Universitario de Alicante. Patient was positioned in left lateral position. The DiLumen was loaded over a 130cm colonoscope, and the device/colonoscope carefully reached the lesion in 12 minutes. The lesion was found to be located behind a fold in a tortuous sigmoid colon. The DiLumen balloons were deployed and inflated to create a stable position near the polyp's location. DiLumen balloons provided improved scope stability, enhanced visualization, and decreased sigmoid tortuosity by flattening haustral folds which made endoscopic polypectomy more feasible. Hot Snare Polypectomy was performed without any complications. The DiLumen device was used as a conduit to remove the specimen and allowed easy reinsertion of the colonoscope to look for any potential mucosal defects. No mucosal defects were found so closure was not deemed necessary. There were no adverse events. Overall procedure time from initial scope insertion to removal of lesion was 32 minutes.



---

### Assessment/Conclusion:

The lesion was classified as low-grade dysplasia, tubular adenoma after histopathological analysis. The DiLumen device helped avoid colectomy by facilitating an easier endoscopic approach to therapy for this patient.



**DR JUAN F MARTÍNEZ**

Gastroenterólogo Adjunto  
Unidad de Endoscopias  
Hospital General Universitario de Alicante,  
Spain



**LUMENDI**

253 Post Road West, Westport, CT 06880  
Tel: (203) 463-2669 Fax: (203) 557-0459  
[Lumendi.com](http://Lumendi.com)